2nd Edition of the Contest of Clinical Cases related to the non-surgical clinical management of kidney stones

Title: Oral and local chemolysis via nephrostomy for treatment of radiolucent stones

Keywords: oral chemolysis, percutaneous chemolysis and radiolucent stones

Authors: María Negueroles-García, Jorge Panach-Navarrete, José María Martínez-Jabaloyas

1. Summary

Objective: To report a clinical case about the use of oral and local chemolysis by nephrostomy catheter for the treatment of radiolucent stones. In addition, a review of the published literature was carried out.

Material and methods: Retrospective evaluation of a patient treated by oral and local chemolysis. A review of the literature in Pubmed was carried out introducing the terms: oral chemolysis, percutaneous chemolysis and radiolucent stones.

Results: 90-year-old male, multi-pathological, who required nephrostomy due to pyelonephritis secondary to radiolucent stones in the proximal ureter. After resolution of the infectious condition, surgery was attempted by anterograde and retrograde ureterorenoscopy without success because the kidney stone was found in a ureteral loop. It was decided to perform oral treatment with Lit-control pH Up and local chemolysis with 1/6 molar sodium bicarbonate through the nephrostomy, which led to the disappearance of the lithiasis.

Conclusions: We considered alkalizing oral chemolysis together with local nephrostomy, a useful treatment option in those patients with radiolucent calculi.

2. Introduction

The prevalence of kidney stones is estimated to be around 1-20%, varying according to geographic area, climatic, ethnic, dietary and genetic factors[1]. Kidney stones can be divided according to their aetiology (infective, non-infective, caused by genetic defects or medication), size, location, composition, risk of recurrence and imaging behaviour[1]. This last point is important as, depending on their mineral composition, they will be radiopaque or radiolucent on plain radiography.

Among the radiolucent lithiasis, those formed by uric acid, ammonium urate, xanthine, 2,8-dihydroxyadenin and drugs (some antibiotics or antiretrovirals) stand out1. Some studies worldwide estimate that uric acid lithiasis affects 6% of the population and that these figures are increasing due to hygienic-dietary changes in recent years[2].

Uric acid is the end product of nucleotide metabolism. The solubility of uric acid is pH-dependent and increases as the urine pH becomes alkaline, so that above 6.5 it is considered soluble.

For this reason, radiolucent stones can be treated by oral chemolysis with potassium citrate, sodium bicarbonate or by ingesting bicarbonated water[3]. In cases where this type of treatment is unsuccessful, depending on the location and size of the stone, different surgical techniques can be used. If the above treatments fail, local chemolysis with alkalinising products has been described[3]. There is little published literature on the use of these solutions. Among the compounds used for local chemolysis are 1/6 molar sodium bicarbonate, trihydroxymethyl aminomethane or tromethanol or tromethamine (THAM) or THAM-E, which has a higher concentration of tromethamine[3].

The aim of this study was to demonstrate, by means of a clinical case, oral and local chemolysis with an alkalinising agent via nephrostomy in a patient with radiolucent stones. In addition, a literature review was carried out on local chemolysis via urinary catheter for the treatment of radiolucent stones by entering the following terms in Pubmed: oral chemolysis, percutaneous chemolysis and radiolucent stones.

3. Description of the clinical case

a) Important background information

We present the case of a 90-year-old man with a personal history of hypertension, hypertensive heart disease, dementia due to Lewy bodies, Parkinson's disease, iron deficiency anaemia and colon cancer, who underwent a left hemicolectomy 15 years ago.

b) Diagnostic support studies and results

He went to the emergency department for abdominal pain and distension accompanied by a fever of 38º at home. Laboratory tests showed a slight deterioration of renal function (creatinine 1.64 mg/dL (baseline 0.8 mg/dL) and an increase in inflammatory and infectious parameters. Urine sediment showed pH 5.5 and uric acid crystals, as well as microhaematuria and leukocyturia. An abdominal X-ray was performed with no images of radiopaque stones, and an ultrasound scan showed right grade III ureterohydronephrosis with no obstructive cause.

c) Diagnosis

It was decided to request an abdominopelvic CT scan showing right kidney grade III ureterohydronephrosis with a 13 mm stone at the level of the distal ureter accompanied by minimal perirenal fluid and fat trabeculation (figure 1a and 1b).

d) Treatment

Given the findings compatible with lithiasic pyelonephritis, it was decided to perform an urgent urinary diversion. In the operating theatre, placement of a double J stent Thus, an 8Ch nephrostomy was performed. After resolution of the infectious process and improvement of renal function, it was decided to perform combined retrograde and antegrade ureterorenoscopy. During surgery, an attempt was made to reach the kidney stone with a flexible ureterorenoscope via the antegrade and semi-rigid ureterorenoscope via the retrograde route, without success. Attempts were made to place a double J stent on the right, but the calculus could not be reached, so it was decided to maintain the right nephrostomy 8Ch and to evaluate different medical treatment alternatives. After surgery, it was decided to start treatment with Lit-Control pH Up (citrate, theobromine, vitamin A and zinc), two pills a day for a month and 20 ml of bicarbonate 1/6 molar per nephrostomy every 12 hours on an outpatient basis for 15 days. Before starting nephrostomy treatment, the urine culture was found to be negative and the patient showed no signs of urinary tract infection.

e) Evolution

The patient presented good tolerance to the treatment, with no complications. An analytical control was performed, and no ionic alterations were observed after instillations. A control abdominopelvic CT scan was requested after the end of treatment (one month after oral chemolysis and two weeks after local chemolysis) in which no ureteral stone was observed in the right renal excretory tract (figure 2a and 2b). The nephrostomy was removed, and a control ultrasound was performed with no alterations observed.

f) Clinical results

During the controls, the patient has remained without the appearance of new calculi.

Below is a table with a review of the literature, including studies that have published cases with local chemolysis via nephrostomy.

Table 1. Literature review of studies presenting clinical cases of local chemolysis by urinary bypass stent.

	Num. patients	Lithiasis-free ratio	Catheter type	Local Chemolysis	Follow-up	No. of patients with side effects (%)	Type of complication
Vandeursen et al. [4] 1991	4	100%	Nephrostomy	Sodium bicarbonate	-	0 (0%)	-
Ebisuno et al. [5] 1987	2	100%	Nephrostomy	THAM	-	1 (50%)	Fever
Lee et al[6]. 1993	10	100%	Nephrostomy	THAM	3 months	1 (10%)	Fever
Nummi et al[7]. 1973	3	100%	Ureteral catheter Nephrostomy	Sodium bicarbonate	4 months	0 (0%)	-

4. Discussion

We present a new case in which oral chemotherapy is combined with local treatment for radiolucent stones. The use of this type of therapy is unusual since, on most occasions, patients can benefit from oral chemotherapy, surgical treatment or both. In our case, as we were dealing with an elderly, multi-pathological patient in whom surgical treatment had been attempted without success, we considered oral and local alkalinisation to be an appropriate therapy. There is no extense published literature on the use of oral and local chemolysis with alkalinising solutions in uric acid stones. Most of the works are old publications, with few patients, which perform local chemolysis through nephrostomy with solutions such as sodium bicarbonate, THAM or THAM-E, without any comparative study between the different drugs to prove the superiority of any of them.

As for the indications for treatment, the alkalinising agents used and the duration vary depending on the published study. Vandeursen et al. used combined therapy using extracorporeal lithotripsy performed with the aid of antegrade pyelography followed by local chemolysis with 1/6M sodium bicarbonate irrigated by nephrostomy[4]. They performed only one session of both therapies combined and verified by antegrade pyelography that there were no stone remnants. This study is not representative of the chemolytic efficacy, as the authors also used extracorporeal lithotripsy.

On the other hand, Ebisuno et al. presented two cases in which they used THAM solution together with oral chemolysis[5]. The first patient did not want to undergo any surgical procedure so it was decided to treat with THAM solution via nephrostomy on a daily basis for 4 weeks accompanied by oral chemolysis. The other patient was a male with residual kidney stones after percutaneous nephrolithotomy. He was treated with THAM solution for 2 weeks on a daily basis. In both patients the uric acid stones disappeared. In our case, due to the patient's multiple comorbidities, the difficulty of surgical access due to the loop in the distal ureter where the stone was embedded, and the fact that the patient had a urinary diversion that would facilitate the process, it was decided that the most appropriate option was to perform local chemolysis combined with oral chemolysis with alkalinising agents.

Regarding adverse effects, local chemolysis can generate fever or low back pain as more frequent side effects[9]. In addition, there is a risk of urinary sepsis secondary to manipulation of the urinary tract, so it is essential to rule out urinary tract infection before starting treatment[9]. In the published literature, Vandeursen et al. did not present any side effects in their patients after instillation of sodium bicarbonate 1/6 M[4]. Lee et al. treated 10 patients using lithotripsy and subsequent solution with THAM 0.1M and 0.02% chlorhexidine[6]. Only one patient developed a fever after treatment and was treated conservatively. In our case, the patient did not present any side effects during or after treatment with oral and local chemolysis.

Treatment duration and recurrences vary according to the different studies. The average duration of treatment is between 9 - 15 days. In our case, the patient was treated for 15 days with local treatment and one month of oral treatment. In most studies, the follow-up of the patient is not explained. Nummi et al. presented three patients with uric acid lithiasis who were followed up for 4 months after local chemolysis without complications[7]. In our case, the patient has remained asymptomatic and no new stones have formed to date.

It is important to highlight the combination of more local oral chemolysis as an effective treatment action. Currently, there are different alkalizing drugs that have been shown to be suitable in the solution of uric acid stones, including potassium citrate and sodium bicarbonate. Trincheri et al. treated 8 patients with oral chemolysis for uric acid calculi using 40 mEq of potassium citrate and 20 mEq of potassium bicarbonate for 12 weeks[10]. Complete dissolution occurred in 3 cases and partial in the remaining ones. In our case, it was decided to use Lit-Control pH Up for its adequate combination of potassium citrate, magnesium citrate and theobromine, since these are powerful alkalizers.

On the other hand, there are studies that demonstrate the efficacy of maintenance treatment with alkalizing drugs[11]. Rodman et al. followed 17 patients treated with potassium citrate at doses of 50 mEq/day and sodium bicarbonate[11]. An increase in urinary pH was generated and there was no recurrence of lithiasis in 2.5 years. In our case, the patient has not generated recurrences in the follow-up period.

As for the limitations of our study, it should be noted that only one patient was studied.In addition, we have not obtained conclusive data on the appropriate dosage of chemolysis by nephrostomy, as the different studies use different doses, alkalinising solutions or vary in duration.

5. Conclusions and recommendations

We consider oral alkalinising chemolysis together with local chemolysis by nephrostomy to be a useful treatment option in patients with radiolucent stones. According to the literature reviewed, it is a well-tolerated treatment modality with few side effects and high resolution rates.

6. References

*1. Türk C, Neisius A, Petrik A, et al. EAU Guidelines on Urolithiasis. Eur Assoc Urol 2020. 2020;69(3):475–82.

2. Morales-Martínez A, Melgarejo-Segura T, Arrobal-Polo MA. Epidemiología de la litiasis urinaria en el mundo y en España. Arch Esp Urol. 2021;74(1):4–14.

*3. Bernardo NO, Smith AD. Chemolysis of urinary calculi. Urol Clin North Am. 2000;27(2):355–65.

*4. Vandeursen H, Pittomvils G, Baert L. Combined extracorporeal shock wave lithotripsy and percutaneous alkalinization in uric acid calculi. Urol Int. 1991;46(1):27–8.

*5. Ebisuno S, Fukatani T, Yoshida M, et al. Percutaneous Dissolution of Uric Acid Calculi with THAM Irrigation. Urol Radiol. 1987; 9:146–8.

*6. Lee YH, Chang LS, Chen MT, Huang JK. Local chemolysis of obstructive uric acid stone with 0.1/M THAM and 0.02% chlorhexidine. Urol Int. 1993;51(3):147–51.

*7. Nummi P. Dissolution of uric acid stones by local lavage. Scand J Urol Nephrol. 1973;7(2–3):172–4.

**8. Kachrilas S, Papatsoris A, Bach C, et al. The current role of percutaneous chemolysis in the management of urolithiasis: Review and results. Urol Res. 2013;41(4):323–6.

*9. Trinchieri a, Esposito N, Castelnuovo C. Dissolution of radiolucent renal stones by oral alkalinization with potassium citrate/potassium bicarbonate. Arch Ital Urol Androl. 2009; 81: 188-91.

*10. Rodman JS. Prophylaxis of uric acid stones with alternate day dosis of alkaline potassium salts. J Urol. 1991 Jan; 145(1): 97-9.

7. Images

Figure 1and 1b

Figure 1a. Coronal cut in which right grade III ureterohydronephrosis with 13 mm stone (yellow arrow) is observed at the level of the right distal ureter located in a ureteral loop. Perirenal free fluid associated with fat trabeculation is also appreciated.

Figure 1b. Cross section in which 13 mm stone is observed in the right distal ureter (yellow arrow).

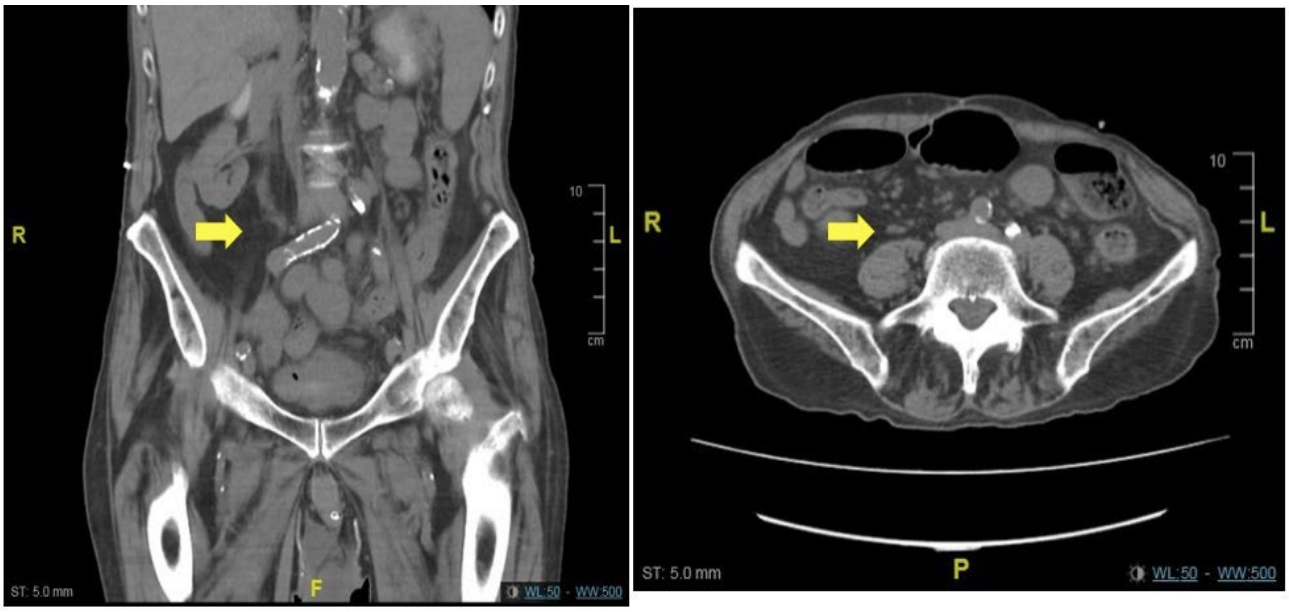

Figure 2and 2b

Figura 2a. Coronal cut in which the absence of stones in the right ureter (yellow arrow) is observed.

Figure 2b. Cross section in which the absence of stones in ancient location (yellow arrow) is appreciated.